



ISSN: 0976-3376

Available Online at <http://www.journalajst.com>

ASIAN JOURNAL OF  
SCIENCE AND TECHNOLOGY

Asian Journal of Science and Technology  
Vol. 11, Issue, 02, pp.10761-10766, February, 2020

## RESEARCH ARTICLE

### A NEW APPROACH TO MANAGE FLABBY RIDGE –A CASE REPORT

<sup>1,\*</sup>Dr. Sasirekha, K., <sup>2</sup>Dr. Padmaja, S. and <sup>3</sup>Dr. Malathi Dayalan

<sup>1</sup>Post graduate student, Department of Prosthodontics, The Oxford Dental College, Bangalore

<sup>2</sup>Reader, Department of Prosthodontics, The Oxford Dental College, Bangalore

<sup>3</sup>Head of the Department, Department of Prosthodontics, The Oxford Dental College, Bangalore

#### ARTICLE INFO

##### Article History:

Received 25<sup>th</sup> November, 2019  
Received in revised form  
19<sup>th</sup> December, 2019  
Accepted 07<sup>th</sup> January, 2020  
Published online 28<sup>th</sup> February, 2020

##### Key words:

Flabby Ridge, Special Window  
Technique, Liquid Supported Complete  
Denture, Vacuum Heat Pressed,  
Polyethylene Sheet, Glycerin.

#### ABSTRACT

Prosthodontic management of flabby ridges in completely edentulous patients poses a challenge to the clinician since the mobile tissue can cause transfer of undue forces to the ridge causing loss of retention, stability and support of the dentures and trauma to the underlying tissue. This case report describes the comprehensive management of flabby ridges by using a special window impression technique and fabricating a liquid supported denture in order to ensure recording of the tissue in undisplaced state and prevent trauma to the underlying tissues respectively.

**Citation:** Dr. Sasirekha, K., Dr. Padmaja, S. and Dr. Malathi Dayalan, 2020. "A new approach to manage flabby ridge –a case report", *Asian Journal of Science and Technology*, 11, (02), 10761-10766.

**Copyright** © 2020, Sasirekha et al. This is an open access article distributed under the Creative Commons Attribution License, which permits unrestricted use, distribution, and reproduction in any medium, provided the original work is properly cited.

## INTRODUCTION

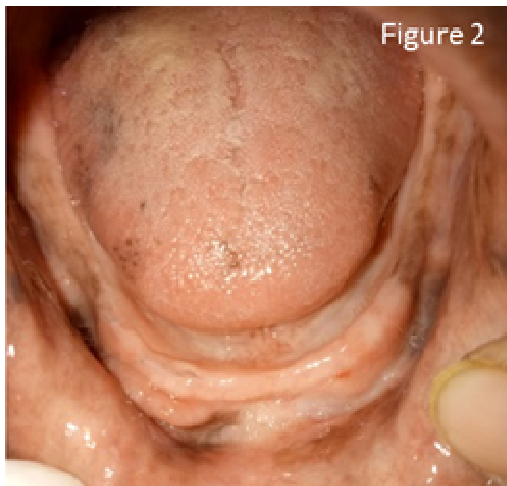
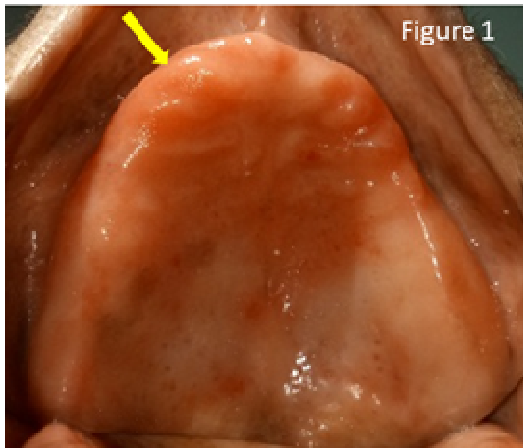
Flabby ridge is a superficial area of mobile soft tissue affecting the maxillary or mandibular alveolar ridges. It can develop when hyperplastic soft tissue replaces the alveolar bone and is a common finding in long term denture wearers (Hazarika et al., 2019). Flabby ridge is also commonly associated with combination syndrome and in unplanned and uncontrolled dental extraction. Prevalence of flabby ridges vary in either arches, with prevalence of 24% in edentulous maxillae and 5% edentulous mandibles (Pai et al., 2014). Forces exerted on the mobile flabby tissue during impression making and mastication can displace it, leading to altered denture positioning, loss of peripheral seal and poor stability of the fabricated denture (Crawford, 2005). These repeated masticatory forces can also cause trauma to the mucosal soft tissue of the flabby ridge (Shrivastava et al., 2017). The main approaches to the management of flabby ridges are surgical removal of fibrous tissue prior to conventional prosthodontics, implant retained prosthesis and prosthodontics without surgical intervention. Prosthodontics without surgical intervention overcomes problems such as surgical complications, increased bulk of

prosthesis due to removal of tissue, problems associated with the general health of the patient, treatment time and cost; which are faced in the former two approaches (Crawford, 2005). For prosthodontic management without surgical intervention, several special impression techniques have been proposed in literature for recording flabby tissue such as incorporating double spacers, multiple relief holes, or a window in the custom tray used for making the final impression. But these fail to control and uniformly apply the impression material. However by using a modified window technique where a clear custom tray with holes is used, the impression material is easily applied with good visibility (Labban, 2018). A suitable impression technique alone is not adequate to treat a flabby ridge. An elastic flexible material can be incorporated on the tissue surface of the denture to prevent repeated trauma to the mobile flabby tissues. For this, tissue conditioning has been emphasized in literature. But these materials are a temporary alternative due to candidal growth and loss of by-products. Due to these limitations, liquid supported dentures were introduced to offer a more permanent solution (Shrivastava, 2017; Shah Rupal, 2014). This case report describes the management of flabby ridge in a patient with completely edentulous maxillary and mandibular arches using a special window impression technique and a liquid supported complete denture.

**\*Corresponding author:** Dr. Sasirekha, K.,

Post graduate student, Department of Prosthodontics, The Oxford Dental College, Bangalore.

**Case report:** A 55 year old female patient reported to The Department of Prosthodontics, The Oxford Dental College, Bangalore with completely edentulous maxillary and mandibular arches. She had a history of diabetes since 12 years which was under control. On intra oral examination, she had flabby anterior maxillary ridge and denture stomatitis of the maxillary arch due to ill-fitting dentures which she had been using since 9 years (Figure 1 & 2). The denture was discontinued for a period of 3 weeks during which the denture stomatitis subsided. A special window impression technique and a liquid supported complete denture to help prevent further trauma to the tissues were planned for the maxillary completely edentulous arch which had anterior flabby tissue. The steps for the special window impression technique are as follows:

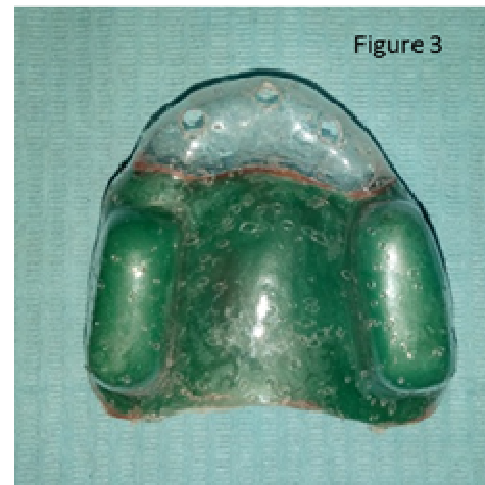


**Figure 1 & 2. Completely edentulous maxillary and mandibular arches with flabby anterior maxillary ridge and denture stomatitis of the maxilla**

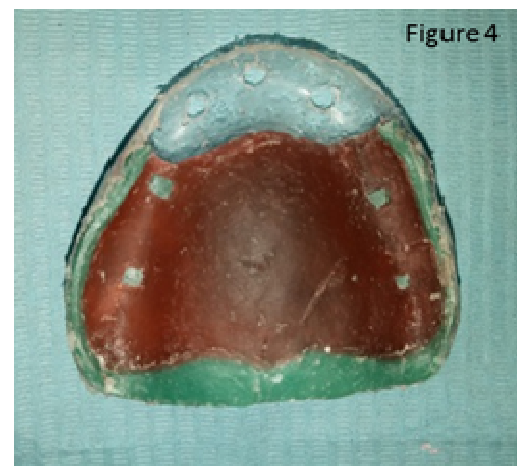
- Primary impressions were made with alginate impression material (Prime Chrome, Prime Dental) using edentulous stock trays.
- The casts were poured in dental plaster and the flabby ridge area was marked on the maxillary cast.
- Custom tray (MP Sai Acrylic Resin Tray material) was fabricated with (spacer of 1 mm; 4 tissue stops) with two posterior handles. Using a sharp blade, the marked area was outlined on the custom tray material during the dough stage but not removed, which will later act as a window.
- After the tray completely polymerized, a clear vacuum heat-pressed hard polyethylene sheet of 1mm thickness

was adapted on the custom tray (Easy-Vac, 3A Medes). The outlined custom tray was removed to obtain a transparent polyethylene window over the flabby tissue area (Figure 3). Three circular vents of equal dimensions were made in the window and blocked using modeling wax until border molding was completed (Figure 4&5).

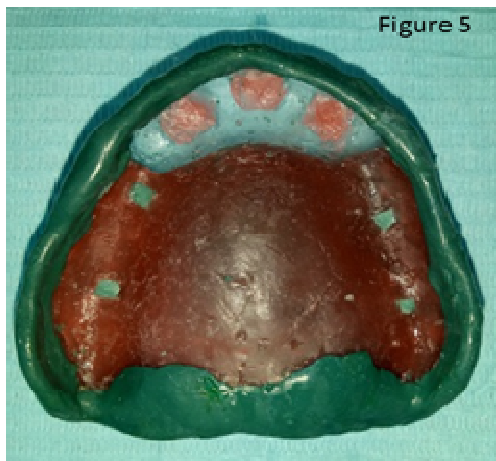
- The tray was placed in the patient's mouth and trimmed 2mm short of the sulcus. Border molding was performed using low fusing compound (DPI Pinnacle green stick compound) (Figure 5).
- Following this, the spacer and wax on the vent holes were removed and tray adhesive was applied.
- Light body hydrophilic vinyl polysiloxane impression material (Reprosil, Dentsply Sirona) was manipulated and applied on the tray except the window area and placed in the mouth. The same material was also injected into one of the vents on the side of the window until it overflowed through the other vents. Border movements were performed (Figure 6).
- After the impression had set, it was removed from the mouth and examined (Figure 7). Master cast was poured in type III dental stone (Goldstone, Asian Chemicals). Mandibular border molding and final impression were made in the conventional fashion using low fusing compound and zinc oxide eugenol impression material (DPI Impression Paste).



**Figure 3. Outlined custom tray was removed to have a transparent polyethylene window over the flabby tissue area**



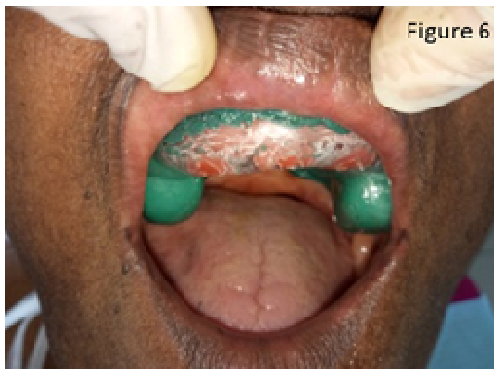**Figure 4. Three circular vents were made in the window**



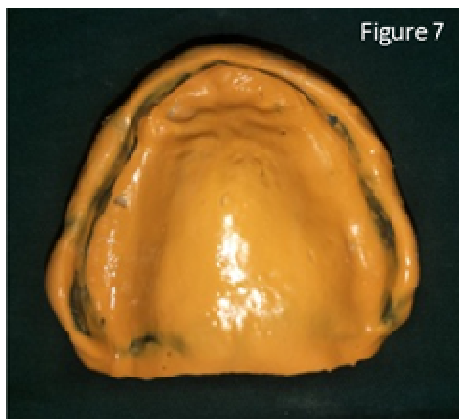
**Figure 5. Vents were blocked using modeling wax & border molding done**

The steps for the fabrication of liquid supported maxillary complete denture are as follows:

- Maxillo mandibular jaw relation and try- in were performed in the conventional method (Hanau Wide Veu Articulator).
- A soft flexible vacuum heat-pressed polyethylene sheet of 1.5 mm thickness was adapted on the maxillary master cast. It was made 2 mm short of the sulcus and then kept aside. It would act as a temporary spacer (Figure 8).
- The maxillary trial denture was then waxed up ensuring that there was a thickness of 3mm on the palatal area (Figure 9).
- After dewaxing, vaseline was applied over temporary sheet, so it can be retrieved easily. Now, the maxillary denture was acrylised using heat cure resin (Colto Cure, Coltene) with the sheet embedded on the tissue side (Figure 10 & 11). The mandibular denture was acrylised in the conventional way.



**Figure 6. Impression material was injected through vent holes**



**Figure 7. Final impression using the special window technique and light body vinyl polysiloxane impression material**

- Finishing and polishing of the dentures were done and were checked in the patient's mouth for retention, stability, support and border extension. In order to get adjusted to the new dentures, the patient was asked to wear it for two weeks (Figure 12 & 13).
- The maxillary denture was then ready to be converted into a liquid supported denture. At recall appointment, a putty impression (Elite P&P, Zhermack) of the tissue surface of the maxillary denture was made and the impression poured with dental stone. In the obtained cast, the junction of the spacer and denture base was marked (Figure 14).
- Following this, the 1.5 mm thick sheet which was used as a spacer was removed from the denture (Figure 15).
- On the cast, a 1mm thick soft flexible vacuum heat-pressed polyethylene sheet was adapted and cut until the marked junction (as opposed to the 1.5mm temporary spacer. This difference in space would be occupied by the liquid).
- The sheet was placed on the tissue side of the denture and the borders were sealed using cyanoacrylate adhesive and auto polymerizing acrylic resin (DPI RR Cold Cure). The seal was checked (Figure 16).
- Then two inlets were made in the denture base on the first molar areas on either side of the denture. A viscous liquid such as glycerin was injected through the inlets. After the space was completely filled, the inlets were sealed off using auto polymerizing resin (Figure 17,18,19& 20).
- The denture was inserted in the patient's mouth and checked for retention, stability and support (Figure 21, 22& 23).
- Post insertion instructions were explained to the patient. Additionally she was advised to make sure that no debris collected in the junction of the flexible sheet and the denture base, to report back to the clinic in case of leakage of liquid, and to make sure she handled the tissue surface of the denture carefully during cleaning.

## DISCUSSION

Flabby ridges can be successfully treated with proper prosthodontic approach, either alone or in combination with surgery and implantology. Surgical removal of flabby tissue is possible if there is adequate bone height. However, it results in short sulcus depth that further needs vestibuloplasty to correct it. Patient convenience, cost and surgical complications are also involved in surgical and implant treatments. Prosthodontic treatment without surgical intervention is a better option in most situations. However, conventional impression techniques used to record flabby tissues often results in poor retentive and stability of the dentures. Creating holes, windows or wax reliefs decreases the hydraulic pressure while impressing flabby areas, thus minimizing the displacement of hypermobile tissues (Crawford, 2005; Deogade, 2017). For the window technique, according to different authors, window has to be prepared either before or after the final impression, and then displaceable tissues recorded statically by painting the flabby tissues with a low viscosity impression material (impression plaster/light body elastomer) through the open window. A clinical challenge here is the difficulty in uniform application and control of low viscous impression material on flabby tissues due to gravitational forces. Also impression plaster is quite brittle and light body elastomer without a custom tray support may have distortions (Labban, 2016).



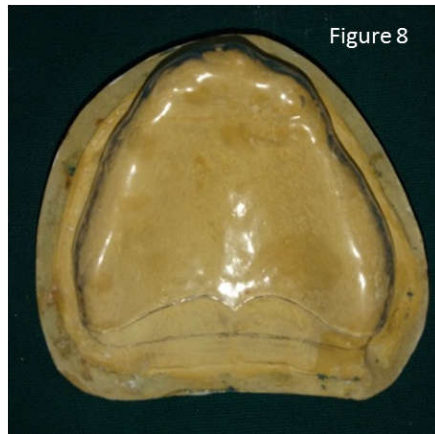

Figure 8. A soft flexible vacuum heat-pressed polyethylene sheet of 1.5 mm thickness was adapted on the maxillary master cast

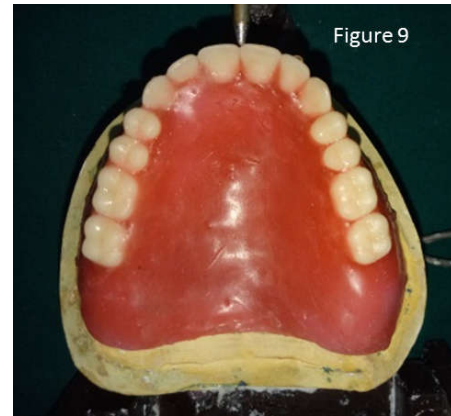


Figure 9. The maxillary trial denture waxed up with a thickness of 3mm on the palatal area

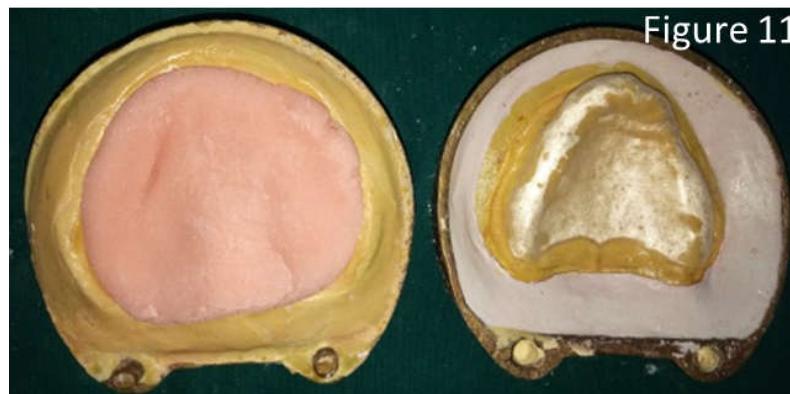
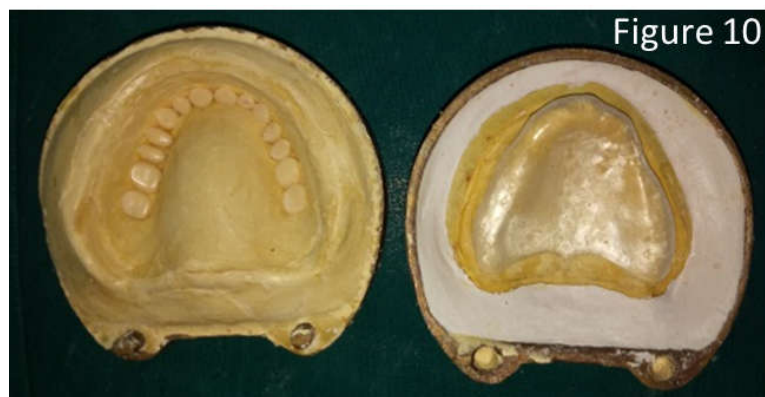
Figure 10 & 11. the maxillary denture was acrylised using heat cure resin with the sheet embedded on the tissue side

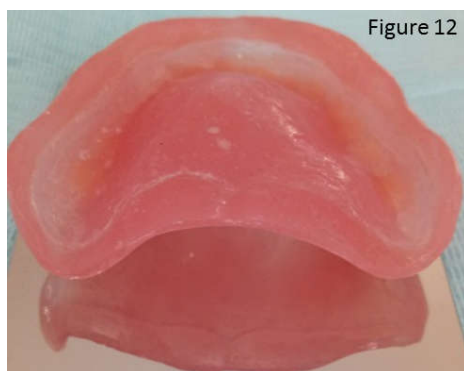


Figure 12. Intaglio surface of maxillary denture.

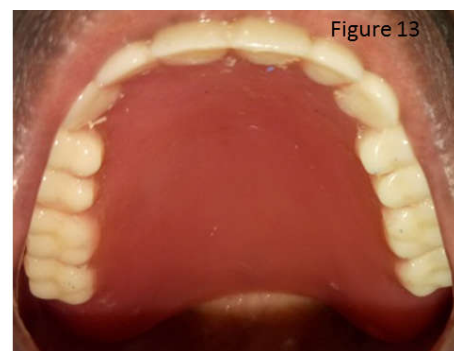


Figure 13. Denture inserted & patient advised to use for 1-2 weeks

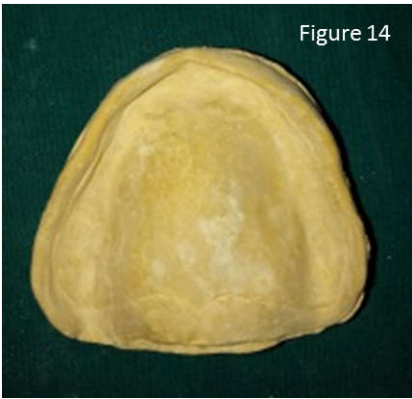

Figure 14. Intaglio surface of the denture is duplicated, 1mm soft, flexible polyethylene sheet adapted on the obtained cast

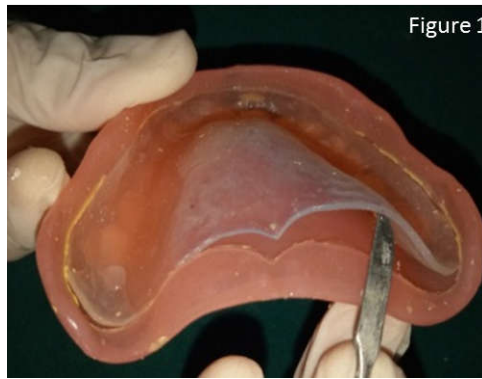

Figure 15. The 1.5 mm thick sheet which was used as a spacer was removed from the denture

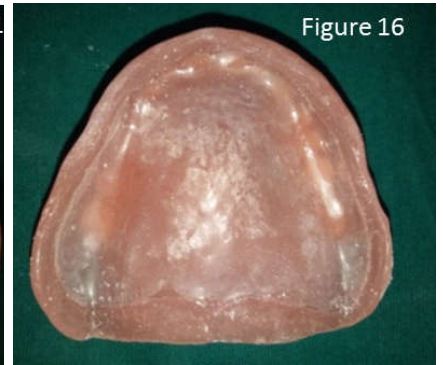

Figure 16. The 1mm sheet was placed on the tissue side of the denture and the borders were sealed using cyanoacrylate adhesive and autopolymerizing acrylic resin

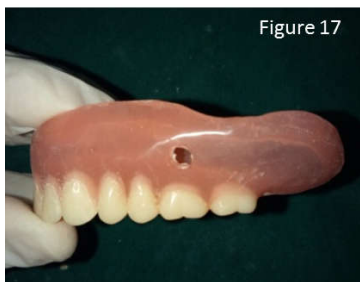


Figure 17. Two inlets were made in the denture base on the first molar areas on either side of the denture

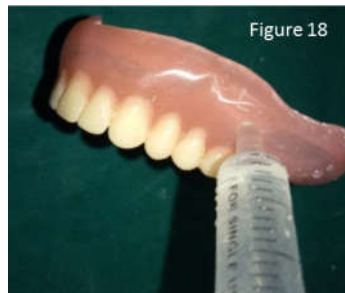

Figure 18. A viscous liquid such as glycerin was injected through the inlets

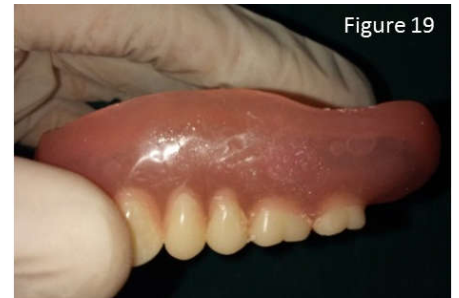

Figure 19. After the space was completely filled, the inlets were sealed off using autopolymerizing resin

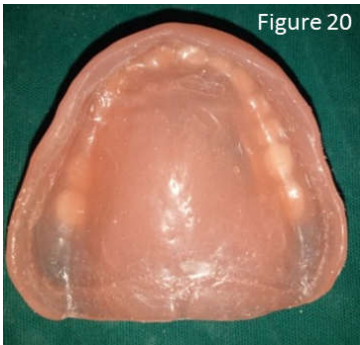

Figure 20. Liquid supported maxillary complete denture

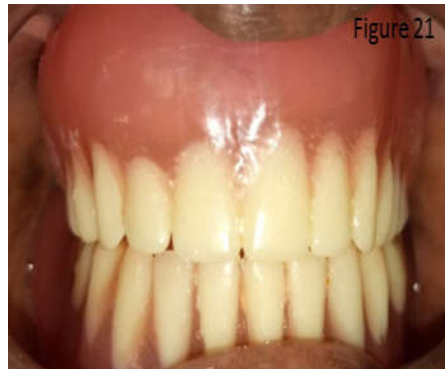

Figure 21. Liquid supported maxillary complete denture inserted

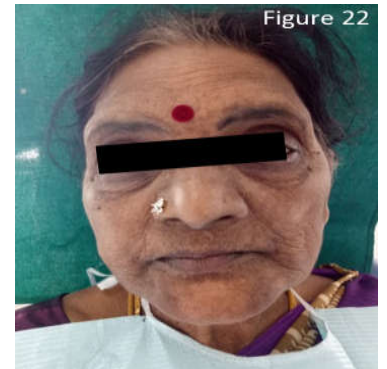

Figure 22. Before insertion of the dentures.

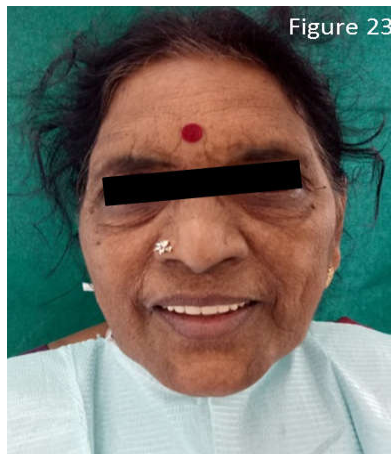

Figure 23. After insertion of the dentures

The special window technique explained in this report allows for controlled application of low viscosity materials in addition to the minimal exertion of pressure to the flabby ridges due to the presence of vents. The polyethylene sheet acted as a stent for holding and preventing the low viscosity material from dropping away from the tissue and giving enough support to prevent distortions. The vents in the polyethylene sheet were appropriately sized to allow for the injecting of light body. Also, the visibility from the clear tray helps clinicians to see the adaptation of impression material to the flabby tissue. Thus this technique can be a better alternative to the conventional window techniques (Labban, 2016). The rationale behind using a liquid supported denture here is that it is flexible and continuously adapts itself to the mucosa because of the flexible sheet and the liquid. However, it is also rigid enough to support the teeth during actual use because of the rigid denture base. It also acts as a continuous reliner for the denture unlike tissue conditioner which is temporary due to candidal growth and release of by-products. When no forces are applied, the flexible sheet remains in the resting position, acting as a soft liner and when the dentures are in use, vertically directed loads are distributed in all directions by the liquid resulting in optimal stress distribution. This helps in long-term preservation of bone and soft tissues. Also, the sheet is dense, which protects the denture from contamination of *Candida albicans* and other microorganisms, thus protecting the mucosa from bacterial or biochemical irritation. For a liquid cushion, glycerine was used which is clear, colorless, odourless and biocompatible (Shah Rupal, ?; Padmaja, 2012). Therefore, it can be used as a more suitable alternative to tissue conditioners and denture conditioners in situations where flabby or abused tissues are present.

### Conclusions

Completely edentulous ridges with flabby tissue can be successfully treated with complete dentures if there is a careful approach to the case from impression making till denture fabrication.

Special window technique with a clear polyethylene sheet acts as a stent for the low viscous impression material and also provides good visibility to ensure proper recording of the mobile flabby tissue in a non-compressed state. Liquid supported dentures act as permanent liners and help in transmission of forces away from the movable flabby tissue while still remaining rigid enough to allow proper mastication. They also prevent further trauma to the already abused tissues.

### REFERENCES

- Crawford RW., Walmsley AD. 2005. A review of prosthodontic management of fibrous ridges. *British dental journal*. Dec;199(11):715-9.
- Deogade S, Gupta P. 2017. Window impression technique: a prosthetic approach to flabby ridges. *Annals Prost & Rest Dent.*, 3:132-5.
- Hazarika P., Pandey S., Tripathi S., Carlo LM., Nayak D. Prosthodontic Management of Flabby Ridges: A Case Report.
- Labban N. Management of the flabby ridge using a modified window technique and polyvinylsiloxane impression material. *The Saudi dental journal*. 2018 Jan 1;30(1):89-93.
- Padmaja S. 2012. Liquid-Supported Denture & Neutral Zone for Atrophic Residual Ridges: A Case Report. *People's Journal of Scientific Research*. Jan; 5(1):52-55.
- Pai UY, Reddy VS, Hosi RN. 2014. A single step impression technique of flabby ridges using monophasic polyvinyl siloxane material: a case report. *Case reports in dentistry*. 2014.
- Shah Rupal J, Prajapati Hardik G, Katyayan Preeti A, Chauhan Vishal R, Bhavyata Darji CS. Innovative Approach–Liquid Supported Denture: A Case Report. *Sch. J. App. Med. Sci.*, 2014; 2(5E):1835-1838
- Shrivastava R, Deogade S, Mantri S. Liquid-supported denture-a boon to flabby ridges. *Annals of Prosthodontics & Restorative Dentistry*. 2017 Jan;3(1):38-41.

\*\*\*\*\*