



ISSN: 0976-3376

Available Online at <http://www.journalajst.com>

ASIAN JOURNAL OF
SCIENCE AND TECHNOLOGY

Asian Journal of Science and Technology
Vol. 10, Issue, 12, pp.10518-10521, December, 2019

RESEARCH ARTICLE

RESULTS AND EVALUATION OF A MODIFIED TECHNIQUE FOR PERCUTANEOUS PINNING OF PROXIMAL HUMERUS

Dr. Pathik Vala¹, Dr. Ajay Devda², Dr. Rutvik Shah^{3,*} and Dr. Vinay bhuria⁴

¹Assistant Professor, LG hospital and AMC MET medial college, Ahmedabad, Gujarat

²Assistant Professor, Banas Medical College, Banas, Palanpur, Gujarat

³Senior Resident, LG hospital and AMC MET medial college, Ahmedabad, Gujarat

⁴Resident, LG hospital and AMC MET medial college, Ahmedabad, Gujarat

ARTICLE INFO

Article History:

Received 25th September, 2019
Received in revised form
09th October, 2019
Accepted 17th November, 2019
Published online 30th December, 2019

Key words:

Proximal Humerus,
K Wire Fixation,
External Fixator, Mini Clamps.

ABSTRACT

Introduction: Proximal humeral fractures are extremely common injuries, and are one of the true osteoporotic fractures. For those that have moderate to severe displacement, the optimal treatment for the patient has not been fully elucidated. The purpose of this study was to evaluate the functional outcome of a modification of percutaneous K-wire fixation technique. **Material and methods:** A prospective study was performed on all patients diagnosed with intra-articular proximal humerus fracture presenting to us from June 2016 to June 2018. Only patients with closed, displaced two or three part fractures as per Neer's classification were included in the study. Fractures were managed by close reduction and percutaneous pinning with K wires which were linked by a fixator rod using clamps. Patients were evaluated for functional outcome using the Constant score. **Results:** Twenty seven patients comprising of 18 females and 9 males were followed for an average period of 14 months. Mean age of the patients was 56 years. Fall while walking was the most common mode of injury followed. Mean Constant Score of patients was 77.2. All patients achieved full functional range of motion by the end of 4 months. No nerve injury was reported. **Conclusion:** Modified technique for percutaneous Kwire fixation using the fixator mini clamps and rods is an effective and economical method allowing biological preservation with good results.

Citation: Dr. Pathik Vala, Dr. Ajay Devda, Dr. Rutvik Shah and Dr. Vinay bhuria. 2019. "Results and evaluation of a modified technique for percutaneous pinning of proximal humerus", *Asian Journal of Science and Technology*, 10, (12), 10518-10521.

Copyright © 2019, Pathik Vala et al. This is an open access article distributed under the Creative Commons Attribution License, which permits unrestricted use, distribution, and reproduction in any medium, provided the original work is properly cited.

INTRODUCTION

Proximal humeral fractures are common type of osteoporotic fractures seen in elderly patients. Women are affected two to three times as often as men (Court-Brown, 2001). Non-displaced proximal humeral fractures can be treated conservatively; displaced ones are often treated surgically. Osteoporosis makes surgery much harder. There are still no evidence-based guidelines for the treatment of proximal humeral fractures. Although proximal humeral fracture is a common type of fracture, very few randomized trials of its treatment have been published. The wide variety of fracture morphologies and treatment options, ranging from conservative treatment to various osteosynthesis methods to the implantation of an endoprosthesis, makes such trials difficult to initiate (Burkhart, 2013). It is universally recognized that non-displaced fractures can be treated conservatively.

In these fractures, the surrounding soft tissues are generally intact, and the periosteal, rotator cuff, and joint capsule serve to stabilize the fracture. Valgus impacted fractures are also a good indication for conservative treatment. The threshold values of Neer (<1 cm, <45 degrees) are generally used for clinical decision-making in elderly patients, and those of Lill (<0.5 cm, <20 degrees, <0.2 cm tubercle displacement) for younger patients (Lill, 2010). The goal of surgical reconstruction is always the anatomical reposition and stable fixation of the fracture. Percutaneous K-wire osteosynthesis is mainly suitable for fractures without metaphyseal comminution. This method is technically demanding and can be performed only if closed reduction is possible. Because the approach is minimally invasive, the perfusion of the humeral head is not compromised. The disadvantages of percutaneous K-wire osteosynthesis include lesser stability and wire-related complications such as migration, infection, and joint perforation. Good clinical results can be obtained in experienced hands with strict patient selection (Bogner, 2008). Open reduction enables better manipulation of the fracture fragments and is therefore suitable for the treatment of any

***Corresponding author: Dr. Rutvik Shah,**
Senior Resident, LG hospital and AMC MET medial college,
Ahmedabad, Gujarat.

type of fracture with plate osteosynthesis. A disadvantage of open internal fixation is difficulty in achieving rigid fixation in the osteoporotic cancellous bone of proximal humerus. Cortical bone in osteoporosis constitutes only a thin shell of bone and provides weak purchase for the screws. Presence of comminution offers difficulty in internal fixation while external fixation works on principal of ligament taxis. Internal fixation has been reported to have increased complication rates in these patients due to hardware loosening and pullout of the screws (Koval et al., 1996; Siegel, 2000; Wijgman, 2002). Additionally, the use of internal fixation device prolongs the operative time, increases intraoperative bleeding, and increases the risk of avascular necrosis of humeral head because of the disruption of the residual vascularity.

Postoperative adhesions further limit the range of motion as a result of extensive dissection needed in cases of open reduction and internal fixation (Neer, 1970). Thus each procedure is has some limitations and complications. A major disadvantage of non-operative treatment is failure to obtain early mobilization, which results in a high rate of shoulder stiffness and pain, and mansion or nonunion is likely with certain fracture types (Hodgson, 2003; Jakob et al., 1991; Zyto, 1995). The purpose of this study was to evaluate the functional outcome of a modification of percutaneous K-wire fixation technique. In this technique, the transfixing K wires were linked together with a fixator rod using mini clamps. This functions like an external fixator but has additional advantage of transfixation.

MATERIALS AND METHODS

A prospective study was performed on all patients diagnosed with intra-articular proximal humerus fracture presenting to us from June 2016 to June 2018. Fractures were classified according to Neer's classification for proximal humerus fractures. Only closed, displaced two or three part fractures and patients of age more than 20 years were included in the study. A written informed consent was obtained from all the patients for inclusion in the study. Patient demographics, injury mechanism were noted and clinical assessment was done. Radiographic evaluation was done with anteroposterior and axillary radiographs of shoulder. Fractures were managed by close reduction and percutaneous pinning with K wires.

Technique: In the case of a two-part surgical neck fracture, or a three-part fracture in which there is significant displacement of the shaft from under the humeral head, a trial reduction is performed to confirm the feasibility of closed reduction and percutaneous fixation. Reduction is performed by applying longitudinal traction with the arm in minimal abduction and some flexion. In case the humeral shaft is anteriorly angulated or displaced, it can be reduced by posterior pressure at fracture site lifting elbow upwards. For varus angulation a lever can be placed through a small incision into the fracture site and maneuvered to reduce it. Alternatively two pins can be passed into head and joysticking can be done. A 2.5-mm terminally threaded pin is held over the shoulder, and a fluoroscopic AP image is obtained. The pin is positioned over the humeral head, coming from the lateral humeral shaft up into the head. A small incision is then made over the lateral arm at the level determined by the fluoroscopic image, and an artery forceps is used to spread the soft-tissue down to the humeral shaft. The tip of the artery forceps can confirm the anterior and posterior cortex of the humerus.

While the assistant maintains the reduction, the surgeon drills the pin, initially horizontally to engage lateral humerus cortex and then up into the humeral head, confirming pin position with either spot radio-graphs or fluoroscopic control until the pin tip is just beneath the articular surface. Head is rotated internally and externally to confirm appropriate pin placement. A second pin is drilled parallel to the first pin in a similar manner. Two pins are passed from the greater tuberosity to engage into the medial cortex of humeral shaft. Additional pins can be inserted to enhance stability. Pins are connected to a fixator rod using mini clamps. Following this shoulder immobilizer was applied for two weeks. Patients were explained pin tract care. They were instructed to daily clean the fixator and shoulder gently with chlorhexidine scrub solution followed by povidone iodine ointment at pin sites. Gentle passive shoulder mobilization was started after 2 weeks. Active mobilization of shoulder was allowed after 4 weeks. The fixator was removed when there were signs of trabecular bridging or periosteal new bone formation on radiographs and clinical improvement in the form of subsidence of pain usually by 8 weeks. Patients were evaluated for functional outcome at 4months, 6 months and 1 year using the Constant score.

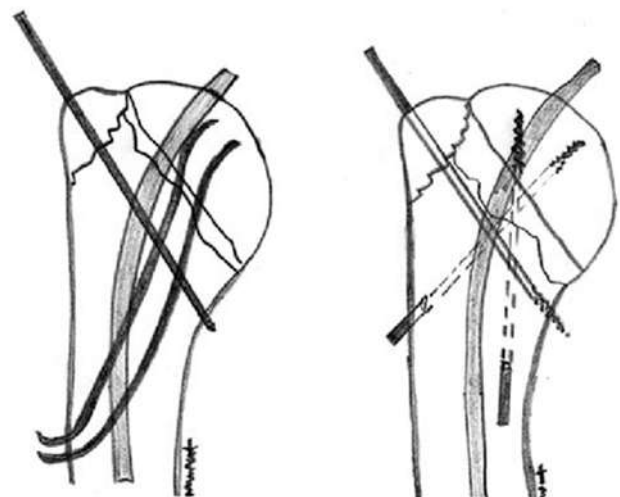


Fig 1. Technique of percutaneous pinning

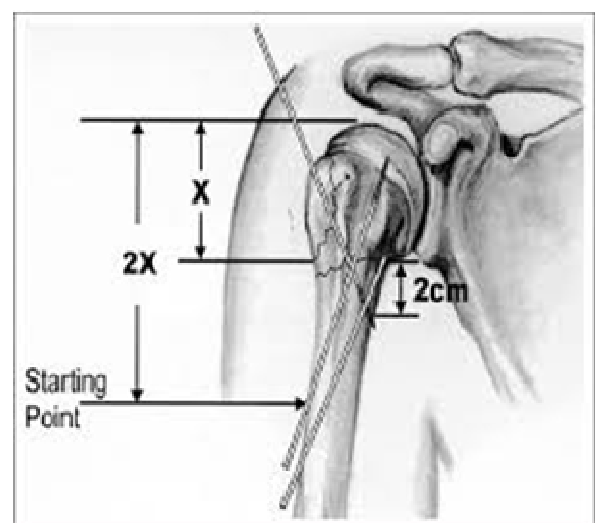


Fig. 2. Inserting points of k wire proximal humerus

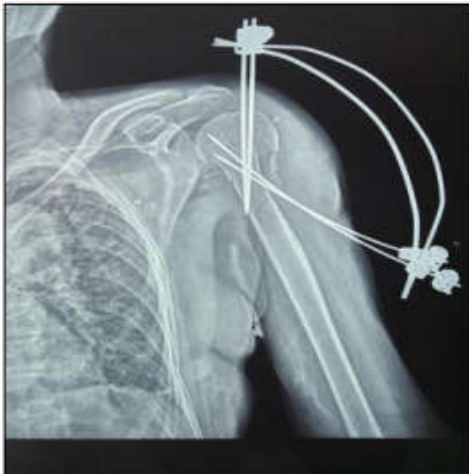

Fig. 3. Postop of Proximal humerus fixator

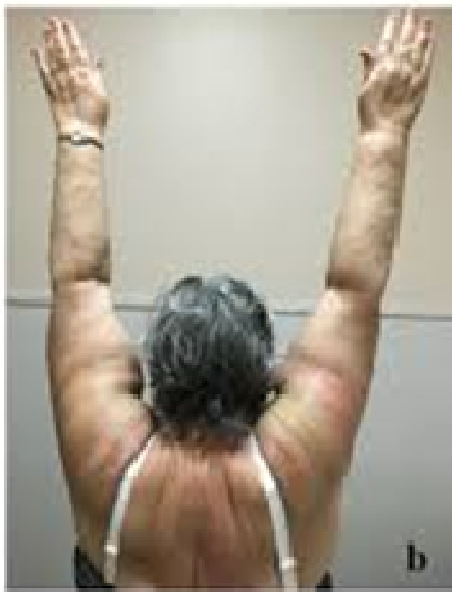

Fig 4. Post of range of motion after 3 months

RESULTS

Twenty seven patients comprising of 18 females and 9 males were followed for an average period of 14 months (range, 12-15 months). Mean age of the patients was 56 years (range, 35-72 years). Fall while walking (22) was the most common mode of injury followed by fall from height (3) and road traffic accident (2). Average time between injury to surgery was 7 days (range, 1-20 day/s). The fracture union time ranged from 6.0 weeks to 10 weeks with mean of 8 weeks. Mean Constant Score of patients was 77.2, with 26% (n=7) patients showing excellent results, 52% (n=14) having good results, and 22% (n=6) having fair results. One patient by the end of first week had penetration of K wires, which were passed from lateral aspect of humerus shaft to subarticular region, into the articular region. These wires were withdrawn under fluoroscopic guidance and reinserted in a different tract. Following this the problem did not recur. Another patient had developed pin tract infection which was managed by regular dressing and antibiotics and the tract healed after removal of pin without any sequelae. All patients achieved full functional range of motion by the end of 4 months. No nerve injury was reported.

DISCUSSION

Fractures of proximal humerus are generally osteoporotic fractures. While conservative treatment may lead to malunion and stiffness, open reduction may lead devascularization of fragments and since most patients are elderly chances of infection and comorbid conditions preventing extensive surgery are higher. A midway between these is close reduction and percutaneous pinning. Problems of K wire loosening and penetration into joint are common. This can be minimized by fixing the wires with clamps to a fixator rod. This allows all K wires to function as a single construct preventing pin migration and loosening. This is functionally similar though not as rigid to a locking plate as locking screws function as bolts in osteoporotic bone. Patient characteristics and injury mechanisms in our study were similar to previous studies; more commonly being an elderly female sustaining trauma to shoulder following a trivial fall (Zyto, 1995; Mills, 1985). In our study, the mean time to radiological union was 2 months, which is comparable to previous studies on use of external fixator in proximal humerus (Gupta et al., 2012; Carbone, 2012). There was only one incidence of pin migration and in none of the cases there was pin loosening in spite of early mobilization. Our study has some limitations, a small sample size at a single centre with absence of controls. Being cost effective and biological, external fixation may be the treatment of choice for displaced proximal humeral fractures, because it preserves the vascularity of the fracture fragments, enables early mobilization avoiding complications associated with pins. Nevertheless this technique has a learning curve and can lead to complications in inexperienced hands.

Conclusion

Closed reduction and percutaneous fixation is a useful technique in select patients with proximal humerus fractures. It is a biological fixation allowing early joint movements with subsequent good results. Also linking the K wires together by means of clamps and fixator rod is an economical way to prevent K wire related complications often seen in postoperative period.

REFERENCES

- Bogner R. et al., 2008. Minimally-invasive treatment of three and four-part fractures of the proximal humerus in elderly patients. *J Bone Joint Surg Br.*, 90:1602-1607.
- Burkhart KJ., Dietz SO., Bastian L., Thelen U., Hoffmann R., Müller LP. 2013. The Treatment of Proximal Humeral Fracture in Adults. *Deutsches Ärzteblatt International*. 110(35, 36):591-597.
- Carbone S., Tangari M., Gumina S., Postacchini R., Campi A., Postacchini F., 2012. Percutaneous pinning of three- or fourpart fractures of the proximal humerus in elderly patients in poor general condition: MIROS® versus traditional pinning. *International Orthopaedics*. 36(6):1267- 1273.
- Clifford PC., 1980. Fractures of the neck of the humerus: a review of the late results. *Injury* 12:91-5.
- Court-Brown CM., Garg A., McQueen MM. 2001. The epidemiology of proximal humeral fractures. *Acta Orthop Scand*. 72:365-371.
- Gupta AK., Gupta M., Sengar G., Nath R., 2012. Functional outcome of closed fractures of proximal humerus managed

- by Joshi's external stabilizing system. *Indian Journal of Orthopaedics*. 46(2):216-220.
- Hodgson SA., Mawson SJ., Stanley D. Rehabilitation after two-part fracture of the neck of the humerus. *J Bone Joint Surg*. 2003; 85:419-22.
- Jakob RP., Miniaci A., Anson PS., Jaberg H., Osterwalder A., Ganz R. 1991. Four-part valgus impacted fracture of the proximal humerus. *J Bone Joint Surg.* 73:295-8.
- Koval KJ, Blair B, Takei R, Kummer FJ, Zuckerman JD. Surgical neck fractures of the proximal humerus: A laboratory evaluation of ten fixation techniques. *J Trauma*. 1996; 40:778-3.
- Lill H., Voigt C. 2010. Proximal humeral fracture. *Z Orthop Unfall*. 148:353-360.
- Mills HJ., Horne G. 1985. Fractures of the proximal humerus in adults. *J Trauma*, 25:801-5.
- Neer CS. 1970. 2nd Displaced proximal humeral fractures. I. Classification and evaluation. *J Bone Joint Surg Am.*, 52:1077-1089.
- Neer CS. 1970. 2nd. Displaced proximal humeral fractures. I. Classification and evaluation. *J Bone Joint Surg Am.*, 52:1077-89.
- Siegel J., Dines D. 2000. Proximal humerus malunions. *Orthop Clin North Am.*, 31:35-49.
- Wijgman AJ., Roolker W., Pall TW., Raaymakers EL., Marti RK. 2002. Open reduction and internal fixation of three and four-part fracture of the proximal part of the humerus. *J Bone Joint Surg.*, 84:1919-25.
- Zyto K., Kronberg M., Brostrom LA. 1995. Shoulder function after displaced fractures of the proximal humerus. *J Shoulder Elbow Surg.*, 4:331-6.
